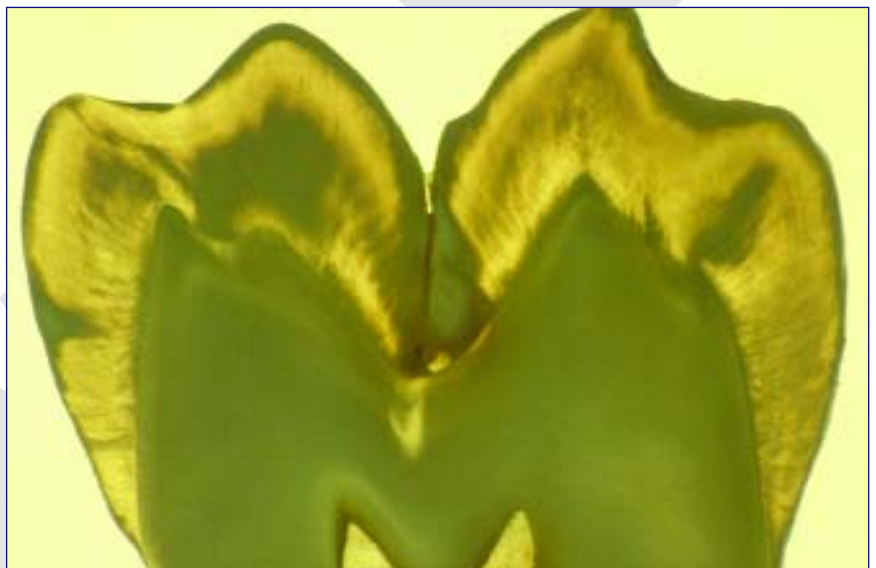


# 14 Classification and Cavity Preparation for Caries Lesions

G. J. Mount ♦ W. R. Hume

As discussed in other chapters of this book, when demineralisation becomes dominant and remineralisation fails, a carious lesion will develop on the enamel or the root surface of a tooth. Once the lesion has progressed into the dentine there is a need for some level of surgical intervention to remove the infected dentine, to eliminate surface cavitation and avoid further accumulation of plaque. In most situations this will involve removal of a certain amount of enamel to achieve access but it must be noted that both enamel and dentine are capable of being remineralised and therefore conserved. The principle of minimal intervention operative dentistry is based upon maximum preservation of natural tooth structure to maintain the strength and integrity of the tooth crown. This Chapter offers a new look at the identification, classification and treatment of lesions from initial demineralisation to the treatment of extensive coronal breakdown.

Up to the present time the profession has used a classification of cavities proposed by G. V. Black over one hundred years ago. The classification was designed before the widespread use of radiographs so lesions were not diagnosed until they were visible to the naked eye and were therefore, by modern standards, relatively large.



A further problem was that it was a classification of cavity designs for amalgam as this was the principal restorative material available. The result was that, regardless of the size of the lesion, a specific cavity design was required to deal with it. Today current knowledge offers many alternatives ranging from earlier diagnosis of caries activity, along with effective methods of control, to the application of adhesive and bioactive restorative materials. If our patients are to reap the full benefit of these advances it is necessary to review both the classification and the approach to the surgical treatment of lesions when they progress beyond remineralisation alone.

## Introduction

**D**efects on the crown or root surface of a tooth can arise from one or more of the following four causes:

- developmental defects in the enamel surface
- bacterial caries
- chemically stimulated dissolution or erosion
- physical abrasion

Probably the most common problem arises from a combination of bacterial caries beginning in relation to a developmental defect. This is confirmed by repeated surveys showing that the most frequent lesion requiring treatment is occlusal caries, primarily in molars but also in bicuspid. The next lesion in terms of frequency is bacterial caries developing in relation to the contact point between pairs of teeth - both posterior and anterior.

In recent years there has been an increasing problem in relation to chemical erosion of both enamel and dentine and this can generally be traced to increased intake of acid food and drink allied to vigorous tooth brushing shortly after intake. Physical abrasion is generally related to occlusal irregularities but can often also be related to chemical dissolution at the same time.

All of these problems can lead to sufficient loss of tooth structure to require repair or replacement but, at the same time, all can be prevented, stabilised or healed to some degree. It is important that there is a means of properly classifying and identifying all these lesions at the time of initial examination so that a proper logical treatment plan can be formulated to not only repair the damage but, more importantly, eliminate the cause.

With this approach in mind this chapter outlines a proposal to introduce a new classification for lesions of the crown of the tooth and then goes on to offer some suggestions for repairing the lesions. It is important to note that the classification does not specify a cavity design. These essential details must be left to the informed and sound clinical judgement of the operator whose main aim at all times should be preservation of as much natural tooth structure as possible.

## A New Cavity Classification

### The reasons for a new classification

**T**he classification used at present by the profession goes under the name of its author, Dr G. V. Black.<sup>1</sup> The centenary for the introduction of this classification is well past and there have been many changes and much progress in the understanding of caries, as well as other forms of progressive loss of tooth structure. The inherent limitations of the present classification are far too rigid for simple modification and it is suggested that it is time to get serious about reviewing the concept.

Probably the most significant discovery that has had a major impact on the practise of operative dentistry is the understanding of the ion migration that occurs, both out of and back into tooth structure, as a result of the caries process. It is now recognised that this is reversible, so the early lesion can be healed and recognition of the initiation of the disease process is imperative. After all, a cavity (loss of tooth substance) is an advanced symptom of a bacterial disease (or chemical dissolution) that has been in progress for some time. It is also apparent that there is a gradation of mineral loss from the heart of the lesion outwards to the periphery of the lesion. This implies that, simply because some section of the tooth is partly demineralised, it does not necessarily have to be removed because remineralisation may still be possible.

The second significant discovery is the development of sound long term adhesion between restorative materials and tooth structure. This not only reduces the potential for microleakage between restoration and tooth but also offers the possibility of reinforcing the tooth crown, at least to the limit of the tensile strength of the material.

A third innovation is the development of a restorative material that is capable of supporting an ion exchange within the tooth crown. This not only leads to an ion exchange mechanism for adhesion but also assists the remineralisation of demineralised enamel and dentine. These three discoveries alone significantly undermine the original precepts behind the G. V. Black classifica-

tion and suggest that there should be change. One of the greatest advantages of introducing a new classification is the possibility of recognising all new lesions from the very earliest stage and treating them in the most conservative minimally invasive manner possible.

At the same time it is necessary to accept that all restorative dentistry up to the time of the introduction of change will have been carried out using Black's principles. In other words, it is essential to take both concepts into account at the same time because it is not possible to carry out a simple substitution of one for the other. Breakdown of old restorations needs to be recognised separately as 'replacement dentistry' and there is little or nothing that can be done for these apart from minimising the loss of further tooth structure.

The following apologia to G. V. Black is offered to assure the reader that the authors understand the historical significance of a great man and a leader of the profession.

### The G. V. Black Concept

When Black defined the parameters for his classification, the cavity designs were controlled by a number of factors many of which no longer apply. Caries was rampant and the role of bacterial flora and the significance of fluoride were not understood. Radiographs were not in general use so, on average, a cavity was not diagnosed until it was large enough to be identified with a sharp probe or seen by the naked eye. By modern standards that meant it was well advanced. There were limitations in the available instruments for cavity preparation as well as the selection of restorative materials. The classification offered a series of cavity designs related to the site of the lesion but the list was then modified to suit the intended restorative material. Because all cavities, by today's standards, were large he did not take into account the increasing dimensions of a cavity nor the varying complexity of the method of restoration. Black suggested that it was necessary to

- remove additional tooth structure to gain access and visibility
- remove all trace of demineralised enamel

and dentine from the floor, walls and margins of the cavity

- make room for the insertion of the restorative material in sufficient bulk to provide strength
- provide mechanical interlocking retentive designs
- extend the cavity to self-cleansing areas to avoid recurrent caries

In his designs Black showed commendable respect for remaining tooth structure as well as occlusal and proximal anatomy but it was necessary to sacrifice relatively extensive areas of enamel and dentine to achieve his goals. Other far more effective methods of dealing with a carious lesion are now available. With modern understanding of adhesion and remineralisation it is no longer necessary to remove all unsupported demineralised enamel around the cavity margin, the concept of self-cleansing areas has been discarded and removal of all affected dentine from the axial wall of the cavity is strictly contraindicated because of the potential for remineralisation and healing.

Many of the old limitations no longer apply and it is now appropriate to think again about the problems presented by a carious lesion. Without in any way denigrating the achievements due to Black's concepts and work, the following thoughts are offered and a new approach to the definition of cavity design is outlined. The proposed classification is designed for the identification of lesions from the very earliest stage of demineralisation and to define their increasing complexity as the lesion extends. It is expected to provide benefits for both the profession and their patients.<sup>2,5</sup>

### Classification of lesions of the exposed tooth surface

It is suggested that caries lesions occur in only three sites on the crown or root of a tooth, that is, in those areas subject to the accumulation of plaque. Therefore, the first parameters for the classification are these sites:

- **Site 1** – pits, fissures and enamel defects on occlusal surfaces of posterior teeth or other smooth surfaces

- **Site 2** – approximal enamel in relation to areas in contact with adjacent teeth
- **Site 3** – the cervical one third of the crown or, following gingival recession, the exposed root

However, as caries can be a progressive disease, it is desirable to be able to define the size and extent of the lesion at the time of identification and, therefore, the potential complexity of the restorative procedures required for treatment. It is possible then to define five separate sizes as the lesion progresses:

- **Size 0** – the earliest lesion that can be identified as the initial stages of demineralisation. This needs to be recorded but will be treated by eliminating the cause and should therefore not require further treatment,
- **Size 1** – minimal surface cavitation with involvement of dentine just beyond treatment by remineralisation alone. Some form of restoration is required to restore the smooth surface and prevent further plaque accumulation,
- **Size 2** – moderate involvement of dentine. Following cavity preparation remaining enamel is sound, well supported by dentine and not likely to fail under normal occlusal load. The remaining tooth is sufficiently strong to support the restoration,
- **Size 3** – the lesion is enlarged beyond moderate. Remaining tooth structure is weakened to the extent that cusps or incisal edges are split, or are likely to fail if left exposed to occlusal load. The cavity needs to be further enlarged so that the restoration can be designed to provide support to the remaining tooth structure,

- **Size 4** – extensive caries or bulk loss of tooth structure e.g. loss of a complete cusp or incisal edge, has already occurred.

The Size 0 lesion will be new and may be difficult to identify. The immediate treatment will be to eliminate the disease and thereby bring about remineralisation. Size 1 lesions will necessarily also be a new lesions and minimal cavity designs, followed by restoration with adhesive materials, will be indicated. Sizes 2, 3 and 4 may mean a new lesion that has progressed to a considerable extent without the patient presenting for treatment or it may be replacement dentistry following breakdown of an old restoration. The same basic principles for developing a cavity design will apply in both cases and, for obvious reasons, the larger the cavity the greater the problems in restoration and the shorter the probable longevity of the plastic restorative materials. The selection of the most suitable material for the larger restorations will be dictated by such properties as resistance to fracture and flexure as well as abrasion resistance.

To assist in communication the relationship between Black's classification and the modern site and size concept is shown below.

#### Site 1: Size 0, 1, 2, 3 and 4 - Pit and fissure caries

- Cavity located on the occlusal surface of a posterior tooth or any simple enamel defect on an otherwise smooth surface of any tooth.
- **Black Class I** – the smaller Sizes 0 and 1 could not be carried out previously because suitable restorative materials were not available so the Black classification begins with Site 1, Size 2 (1.2).

**TABLE 14.1: Classification of caries lesions**

SIZE SITE	No cavity 0	Minimal 1	Moderate 2	Enlarged 3	Extensive 4
Pit/fissure 1	1.0	1.1	1.2	1.3	1.4
Contact area 2	2.0	2.1	2.2	2.3	2.4
Cervical 3	3.0	3.1	3.2	3.3	3.4

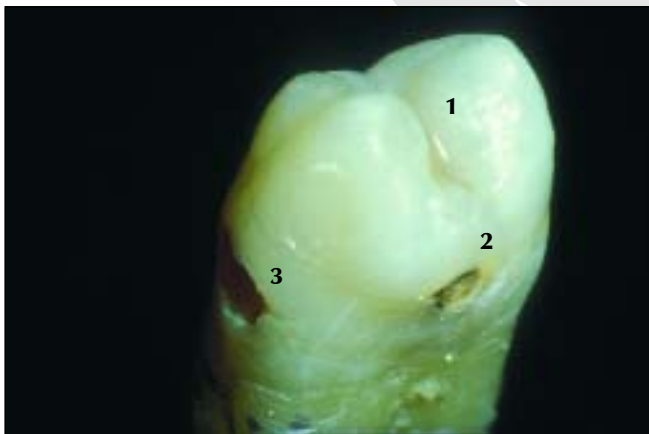**Table 14.1.** A diagrammatic representation of the proposed classification so that the user can visualise the relationship of the Site and Size concept for the description of lesions of the crown of a tooth.

**Site 2: Size 0, 1, 2, 3 and 4 – Approximal lesion commencing in relation to contact areas**

- Cavity located on the approximal surface of any tooth (anterior or posterior) initiated in relation to the contact area between two teeth.
- **Black Class II** – lesions occurring between posterior teeth only. Because of difficulties of identification and materials limitations there was no equivalent of Size 0 or 1 so the Black classification begins with Site 2, Size 2 (2.2).
- **Black Class III** – lesions occurring between anterior teeth only.
- **Black Class IV** – an extension of a Class III lesion involving the incisal corner or incisal edge of an anterior tooth. An alternative cause would be traumatic fracture of the incisal corner – now classified Site 2, Size 4 (2.4).

**Site 3: Size 0,1,2,3 and 4 – Cervical lesions**

- Lesion located in the cervical region anywhere around the full circumference of a tooth including exposed root surface following recession.
- **Black Class V** – this classification does not recognise lesions on the gingival third of the approximal surface, particularly root surface



**Fig. 14.1.** The crown of a bicuspid tooth showing the three Sites where caries is normally initiated: 1. occlusal fissures, 2. proximal contact areas, 3. cervical regions around the full circumference of the tooth.

**Table 14.2.** Demonstrating the difference between the original G. V. Black classification and the new proposal. The main difference is that the earliest signs of demineralisation can be recorded with this system and the numerical identification fits well with computerisation of records.

TABLE 14.2: Comparison	
Proposed classification	Equivalent Black classification
<b>Site 1 – Pits and fissures and smooth surfaces</b>	<b>Class I – Pits &amp; fissures</b>
Size 0 – fissure seal	Not classified
Size 1 – minimal surgery	Not classified
Size 2 – equivalent to Black Class 1	Class I
Size 3 – requires protection of remaining tooth structure	Class I
Size 3 – lost cusp or similar	Class I
<b>Site 2 – Contact area, all teeth</b>	<b>Class II – contact area, posterior teeth</b>
Size 0 – surface demineralisation	Not classified
Size 1 – beyond remineralisation	Not classified
Size 2 – moderate involvement	Class II
Size 3 – requires protection of remaining tooth structure	Class II
Size 4 – bulk loss of tooth structure	Class II
	<b>Class III – contact area, anterior teeth</b>
	Not classified
	Not classified
	Class III
	Class III
	Class III
	<b>Class IV – incisal edge lost, anterior tooth</b>
	Not classified
	Not classified
	Class IV
	Class IV
	Class IV
<b>Site 3 – cervical third</b>	<b>Class V – cervical third</b>
Size 0 – surface demineralisation	Not classified
Size 1 – minimal intervention	Not classified
Size 2 – more extensive	Class V
Size 3 – approximal root surface	Class II
Size 4 – two or more surfaces	Class V

caries, as being different from Class II lesions. An erosion/abrasion lesion or a small carious cavity on the buccal or lingual surface would be a Site 3, Size 0 (3.0) if it was expected to be arrested. If restoration was required it would be Site 3, Size 1 (3.1). A larger carious lesion would be classified as Site 3, Size 2 (3.2). An interproximal lesion would generally be Site 3, Size 3 (3.3) because of difficulty of access. The Site 3, Size 4 (3.4) classification is reserved for a complex lesion involving more than one tooth surface.

### Cavity design and preparation

It will be noted from the above that the Black's classification did not allow for the Size 0 or Size 1 lesion in either Site 1 or 2 because, in the absence of radiographs, they could not be identified. Also, in the absence of adhesive restorative materials the Size 1 could not be repaired in the proposed minimal manner.

It must be recognised that there is a clear division between restoring a new lesion and replacing a failed restoration. When dealing with new active caries the cavity design should be very conservative because it is possible to remineralise both enamel and dentine which is only partly demineralised and not denatured and cavitated. Margins need be extended only to smooth surfaces which are capable of remineralisation and the concept of removal of all demineralised tooth structure on the theory of extension for prevention no longer applies. Cavity outline form should be dictated only by actual cavitation of the surface so this means it is often possible to maintain tooth to tooth contact interproximally. In fact, with the Size 1 and 2 lesion the prime object of the restoration is simply to restore the smooth surface of the crown to prevent further plaque accumulation.

When dealing with an erosion/abrasion lesion it is essential to diagnose and eliminate the cause to ensure longevity for any restorative material chosen for repair.

On the other hand, in replacement dentistry, the cavity outline is already defined and will often be more extensive than ideal. For these restorations most of the principles laid down by Black will still

apply, if for no other reason than tooth structure cannot be replaced. In fact, for both Size 3 and Size 4 lesions very little has changed.

Whether the problem presenting is a new lesion or replacement of a failed restoration, the limitations of the physical properties of both the remaining tooth structure and the restorative material must be taken into consideration. A small restoration can be reliably supported by remaining tooth structure, particularly in the presence of adhesive restorative materials. In fact, it is claimed that a tooth crown can be restored to full physical strength by placing these materials. However, as the cavity enlarges the tooth becomes weaker until it reaches a point where the restoration must be designed in such a way that the restorative material itself will support remaining tooth structure and protect it from occlusal load. This requires modification to cavity designs and some consideration as to which material to utilise. These factors are taken into account within the classification.

With the foregoing in mind, treatment of each of the lesions mentioned in the classification will be discussed. However, it must be noted that there is no intention of specifying the actual cavity design or the method of restoration for any lesion. These decisions are left to the operator to decide according to prevailing conditions for each patient.

## SITE 1 LESIONS

Lesions identified under this classification will generally commence in fissures on the occlusal surface of a posterior tooth. Pits on the lingual of upper anterior teeth are not uncommon and may also occur on the buccal surface of lower molars and the lingual extension of the distal occlusal groove of upper molars. Erosion and attrition lesions on the occlusal surfaces of posteriors and the incisal edges of anteriors should also be included.

- **Site 1 – Size 0 (1.0)**

No equivalent in the G. V. Black classification

A pit or fissure on any tooth or an erosion lesion on an incisal edge that is regarded as

suspicious and in need of observation and preventive measures.

- **Site 1 – Size 1 (1.1)**

No equivalent in the G. V. Black classification

Small defect in one section of a pit or fissure and will often be restored in combination with placement of a fissure seal on the remainder of the fissure system.

- **Site 1 – Size 2 (1.2)**

Moderate size lesion with all fissures involved or replacement of an existing Black Class I restoration.

- **Site 1 – Size 3 (1.3)**

A larger lesion requiring incorporation of protection of one or more cusps within the design.

- **Site 1 – Size 4 (1.4)**

Extensive lesion with one or more cusps already missing

### Site 1 – Size 0, designated 1.0

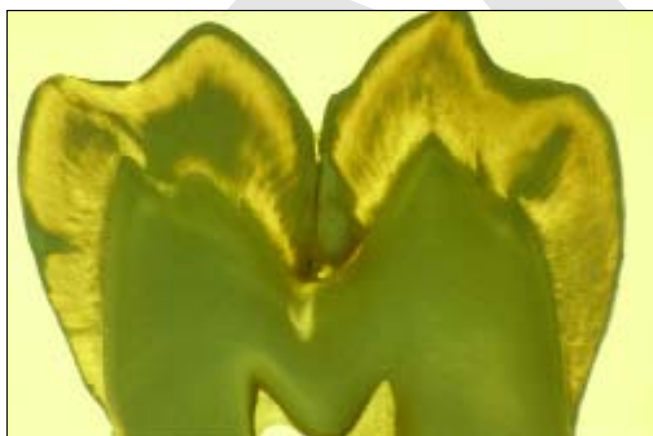
No equivalent in the G. V. Black classification

The typical lesion is generally represented by an occlusal fissure on a posterior tooth. However, there are similar defects in the enamel that can be noted in areas like the cingulum pits at the lingual of upper laterals or the buccal pits on lower molars. The eroded tips of the cusps of posteriors or incisal edges of anteriors can also be recorded

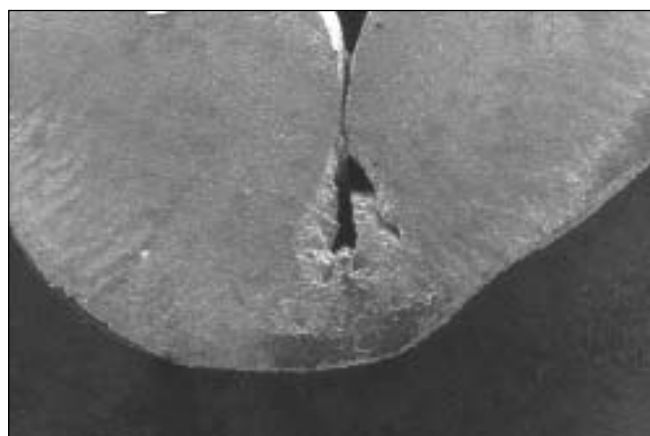
in this category. Specifically these lesions do not need to be restored, simply identified. It is important to diagnose the cause of the lesion and the caries risk situation and prevent progress (**Chapter 6**). This is not always simple but will necessarily require investigations in to the caries status of the patient.

### Anatomy of the fissure system

Before considering the prevention or restoration of a fissure lesion it is necessary to understand the development and anatomy of fissures.<sup>6,7</sup> Diagnosis and treatment of the fissure systems of the posterior teeth has always been difficult and controversial. It seems that nearly all posteriors have complex fissures but for a variety of reasons only a percentage of them become carious (**Figures 14.2 and 14.3**). Fissures form during calcification of the crown of the tooth. Calcification commences at the tip of the cusps and, as the cusps grow, they will fuse to some degree at the completion of the occlusal surface of the crown. Fusion will not always be complete and in a high percentage of cases there will be defects within the area of fusion ranging from single deep pits to extended grooves with limited opening to the outer surface but relatively large defects in the depths of the fissure. It is virtually impossible to determine the



**Fig. 14.2.** A photomicrograph using transmitted light showing the earliest signs of a caries lesion at the base of an occlusal fissure. Note the signs of the development of the translucent dentine below the fissure resulting from the deposition of additional mineral in the lateral tubules as a result of stimulation of the pulp arising from the presence of the caries.



**Fig. 14.3.** A scanning electron micrograph of the same lesion shown in **Figure 14.2**. Note the level of development of the lesion in the enamel without overt signs in the dentine. However, the dentine is already involved as demonstrated in the previous figure.