

# Contents

Introduction	iii
About the Authors	v
Contributors	ix
<b>Case 1</b> Tricholemmoma (desmoplastic) <i>Adriano Piris, Artur Zembowicz, Martin C. Mihm</i>	1
<b>Case 2</b> Sebaceoma <i>Adriano Piris and Martin C. Mihm</i>	9
<b>Case 3</b> Trichoblastoma <i>Steven R. Tahan</i>	15
<b>Case 4</b> Trichodiscoma <i>Steven R. Tahan</i>	21
<b>Case 5</b> High-grade sebaceous carcinoma <i>Stephen Lyle</i>	25
<b>Case 6</b> Apocrine hidradenoma <i>Aaron P. Caplan and Vincent Liu</i>	31
<b>Case 7</b> Malignant nodular hidradenoma <i>George F. Murphy</i>	39
<b>Case 8</b> Prepubertal nevus sebaceus (organoid nevus) <i>Norma Rodriguez, Artur Zembowicz and Zeina Tannous</i>	45
<b>Case 9</b> Pigmented malignant pilomatricoma <i>Thomas J. Flotte</i>	53
<b>Case 10</b> Porocarcinoma (squamous variant) <i>Aaron P. Caplan and Artur Zembowicz</i>	61
<b>Case 11</b> Endocrine mucin-producing sweat gland carcinoma <i>Artur Zembowicz</i>	71
<b>Case 12</b> Nipple adenoma <i>Richard A. Scolyer</i>	83
<b>Case 13</b> Digital papillary adenocarcinoma <i>Richard A. Scolyer</i>	99
<b>Case 14</b> Cutaneous myoepithelioma <i>Thomas Brenn</i>	111
<b>Case 15</b> Microcystic adnexal carcinoma <i>Thomas Brenn</i>	123

## Case History

A 55-year-old male presented to his dermatologist with 'verrucous papule' on the nose. Biopsy was performed to rule out suspected squamous cell carcinoma.

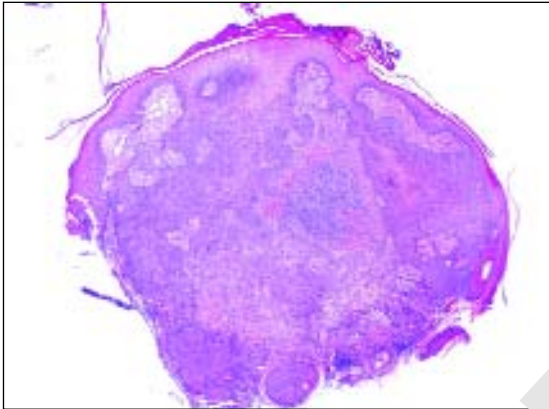


Figure 1

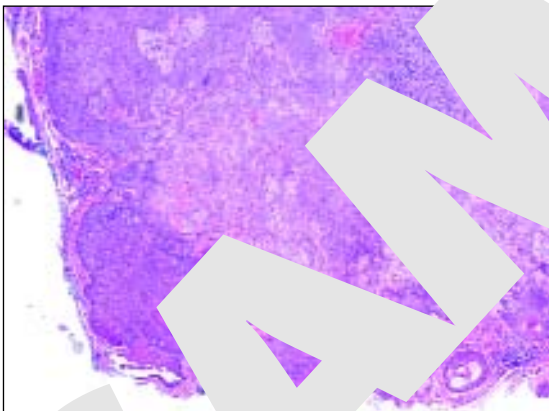
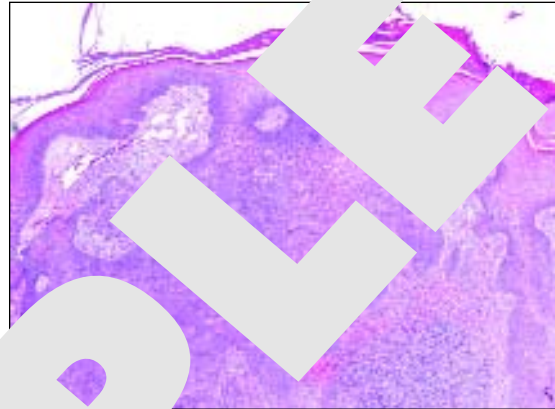


Figure 3

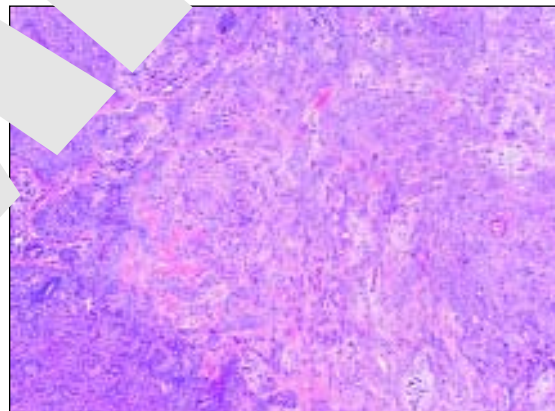


Figure 4

Figure 1: Low magnification view. Note epidermal hyperplasia and multiple points of attachment to the epidermis, well-circumscribed border, and central area of desmoplastic changes.

**Figure 2:** Superficial portion of the lesion.

**Figure 3:** Deeper portion of the lesion.

**Figure 4:** Area of desmoplastic changes. Such architecture can mimic carcinoma.

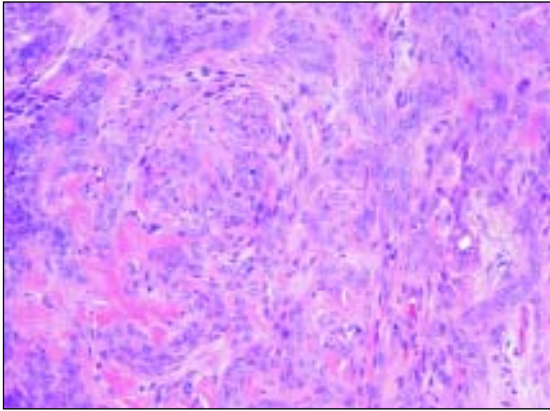


Figure 5

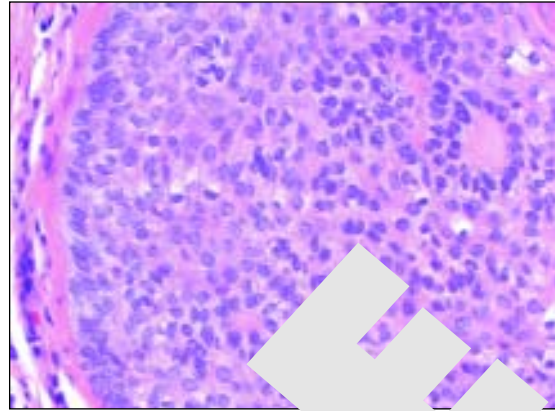


Figure 6

**Figure 5:**

Bland cytological features of tumor cells in area of desmoplasia.

**Figure 6:**

Border of tumor lobules showing tricholemmal (outer root sheath) differentiation: prominent basement layer, peripheral palisading, clear cytoplasm, and visible intercellular borders.

## Diagnosis

Tricholemmoma (desmoplastic).

## Commentary

Tricholemmoma is a benign adnexal neoplasm that shows differentiation resembling the outer root sheath of the hair follicle. It presents clinically as solitary or infrequently multiple pale-tan papule(s), often with hyperkeratotic or overtly verrucous surface. Tricholemmomas can arise in various anatomical locations with particular preponderance on the frontal face. The nose is the most common site. There is no age or gender predominance, but the lesion is most frequently encountered in middle aged or older adults.

The presence of multiple facial tricholemmomas has been associated with Cowden's disease. This disorder is an autosomal dominant genodermatosis characterized by multiple hamartomas and a high risk for breast and thyroid carcinoma. Tricholemmoma is also among the most common tumors arising in nevus sebaceus.

Simple excision is curative in most cases. Only rarely tricholemmoma can recur after an incomplete excision.

This case well illustrates histological features of tricholemmoma. The lesion grows as a single nodule connecting with the overlying epidermis at multiple attachment points. Epidermal hyperplasia is an expected feature in tricholemmoma, but may be absent if the lesion was previously traumatized. Some cases show marked epidermal changes resembling verruca vulgaris. In fact, cytological changes such as focal koilocytosis and prominent hyaline granules, similar to

those observed in verruca vulgaris, may be present. In small early lesions the connection with the follicular outer root sheath can sometimes be appreciated. In most cases origin from the hair follicle cannot be demonstrated. The lesion is composed of small and uniform polygonal cells with lightly eosinophilic or clear cytoplasm. In our case focal squamous differentiation resulting in formation of squamous eddies could be observed in the center of the lesion. In many cases clear cells predominate. The most common diagnostic pitfall associated with tricholemmoma is over interpretation of desmoplastic changes as invasive carcinoma. The architectural pattern in desmoplastic tricholemmoma may be quite concerning with small strands of tumor cells infiltrating sclerotic stroma. However, the tumor cells show limited cytological atypia. In addition, the desmoplastic stroma resembles thickened basement membrane which can be highlighted with PASD stain. As in our case, desmoplastic changes are typically confined to deep and central portion of the lesion and are surrounded by lobules showing more typical features. Exceptionally rarely, desmoplastic tricholemmoma will constitute the major component of the lesion.

The most important diagnostic feature in tricholemmoma is evidence of tricholemmal (outer root sheath) differentiation (**Figs 7 & 8**). It will usually be found at the base or at the lateral border of the lesion. Histologically, outer root sheath differentiation is characterized by: bland epithelial cells showing peripheral palisading, clear cytoplasm, visible intercellular borders and thickened brightly eosinophilic PAS-positive basement membrane.

Tricholemmoma usually express cytokeratins and CD34 antigen on immunohistochemical stains.

Histological differentiation diagnosis of tricholemmoma is broad. Areas of focal tricholemmal differentiation can be found in other adnexal neoplasms including basal cell carcinoma, squamous cell carcinoma, hidradenoma, pilar tumors and other adnexal showing mixed follicular differentiation. Tricholemmal differentiation can also be feature in salivary gland tumors. Tricholemmomas usually show only mild to moderate cytological atypia. The term tricholemmal carcinoma has been reserved for malignant tumors showing pure tricholemmal differentiation. An example of tricholemmal carcinoma at the bland spectrum of atypia is illustrated in **Figures 15-23**.

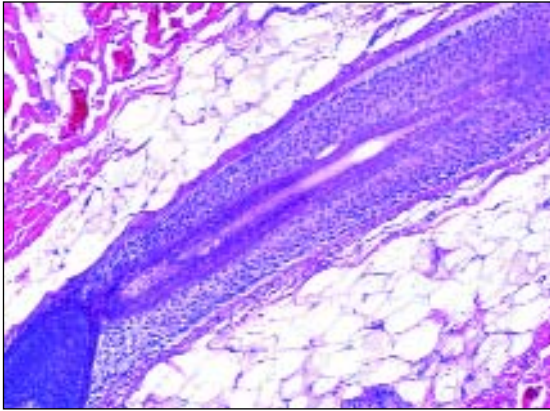


Figure 7

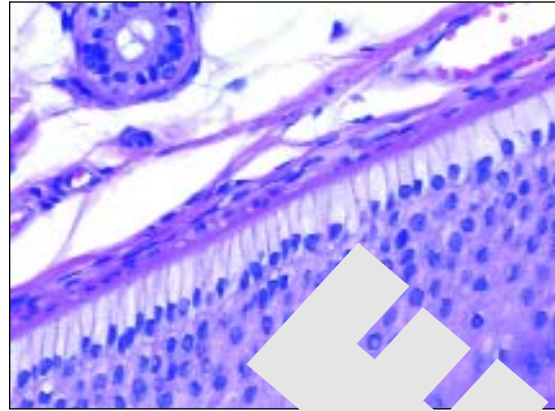


Figure 8

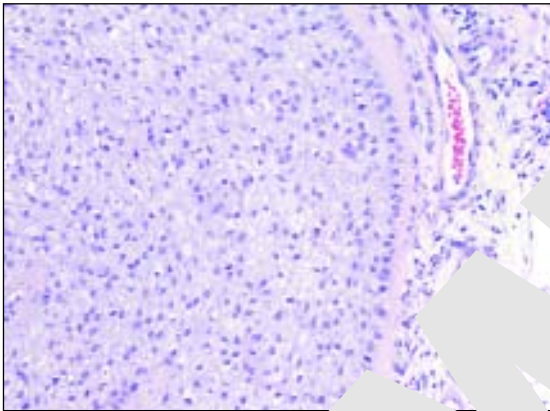


Figure 9

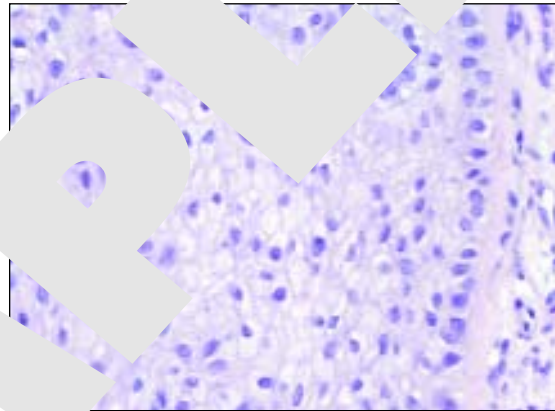


Figure 10

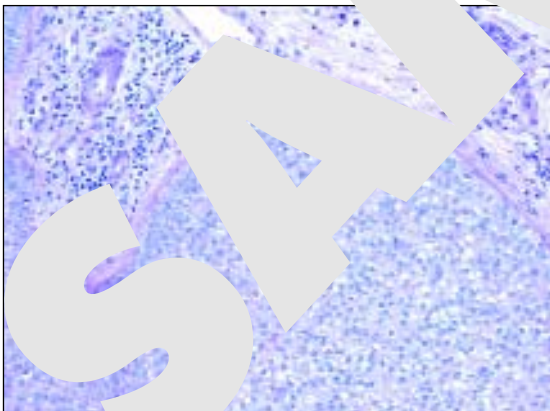


Figure 11

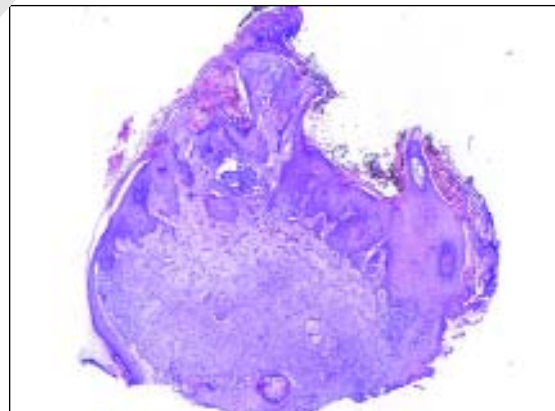


Figure 12

**Figures 7 & 8:** Outer root sheath of a hair follicle showing features of tricholemmal differentiation: prominent basement membrane, peripheral palisading, clear cytoplasm, and visible intercellular borders.

**Figures 9 & 10:** Tricholemmal differentiation in a different case. Clear cell features are common in tricholemmoma.

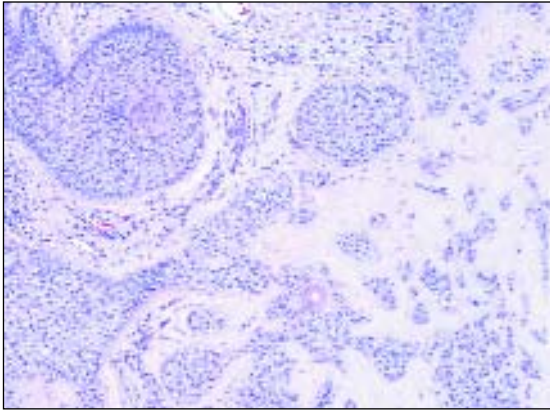


Figure 13

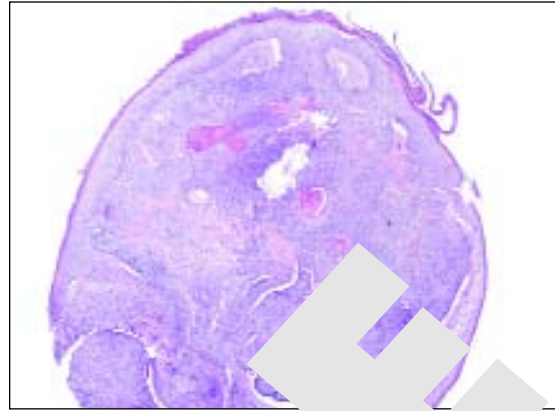


Figure 14

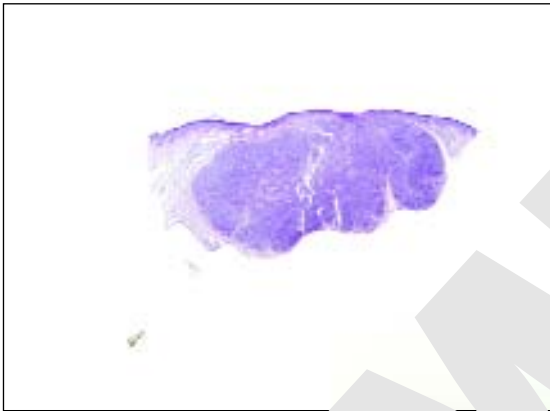


Figure 15

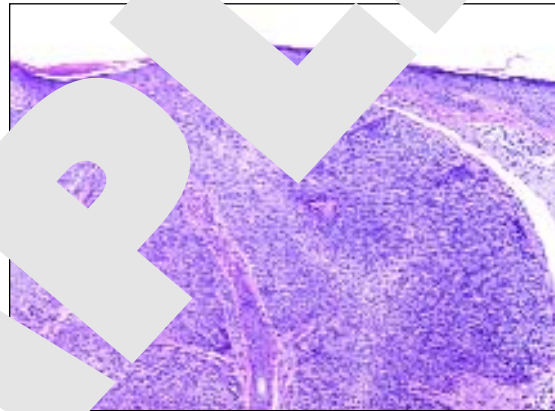


Figure 16

- Figure 11:** PAS-diastrase stain highlights basal membrane (a different case). Clear cell cytoplasm is negative.
- Figure 12:** Marked verrucous hyperplasia in a different case. It has been suggested that tricholemmoma may be an induced by HPV. Indeed, focally epidermal changes may be indistinguishable from those in verruca vulgaris.
- Figure 13:** Desmoplastic areas in tricholemmoma (a different case) may raise histological differential diagnosis of invasive squamous cell carcinoma. The lack of significant cytological atypia and the context of surrounding tricholemmoma are essential for correct classification of such lesion.
- Figure 14:** Scanning magnification in another tricholemmoma showing clefting between well-circumscribed tumor and surrounding stroma which may lead to erroneous diagnosis of basal cell carcinoma.
- Figure 15:** Scanning magnification of tricholemmal carcinoma.
- Figures 16-18:** Tricholemmal carcinoma: superficial portion of the lesion. The lesion is composed of cellular proliferation of polygonal cells with clear cytoplasm and prominent intercellular borders. Note moderate pleomorphism.

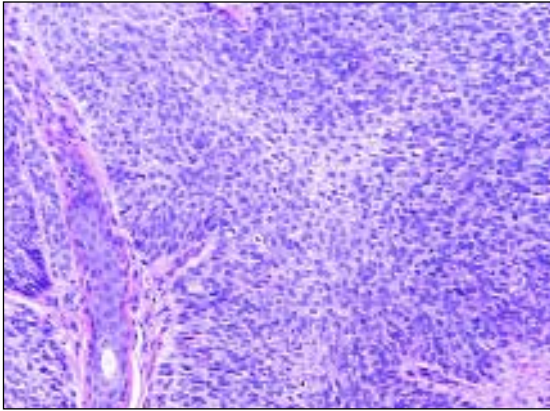


Figure 17

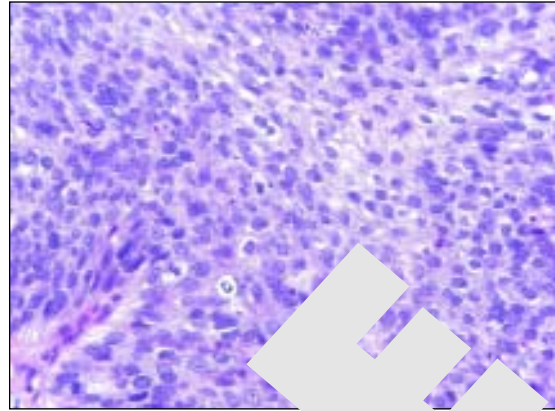


Figure 18

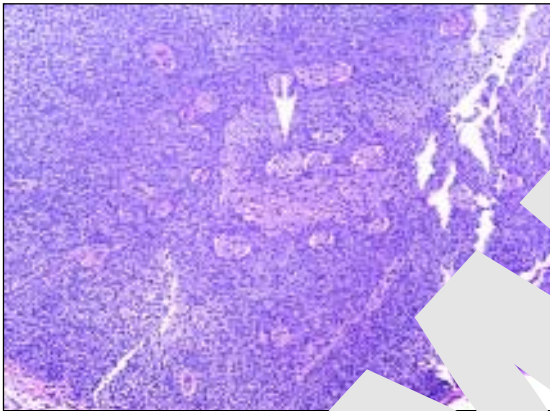


Figure 19

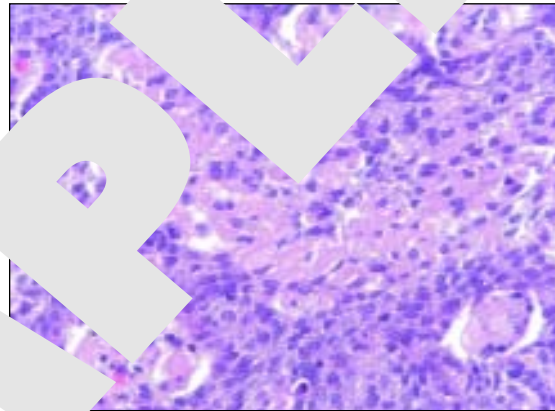


Figure 20

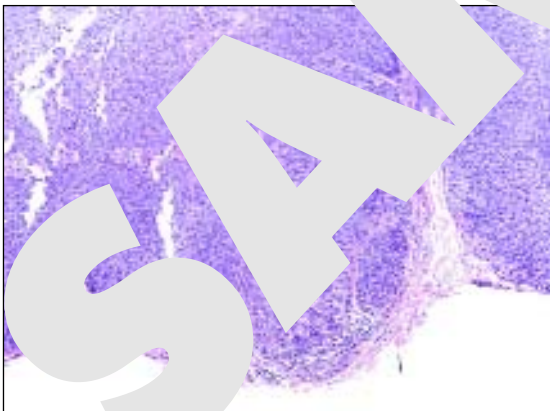


Figure 21

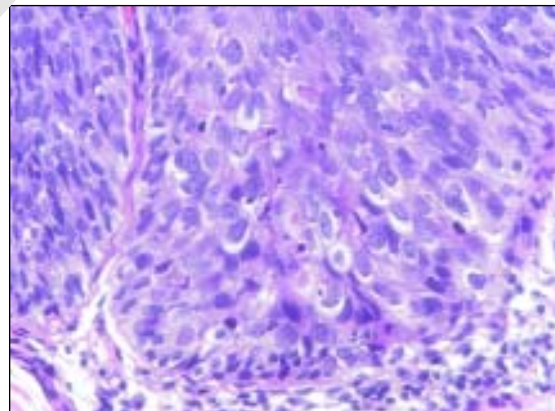


Figure 22

**Figures 19 & 20:** Tricholemmal carcinoma: area of tumor necrosis.

**Figures 21 & 22:** Tricholemmal carcinoma: focus of severe cytological atypia at the deep portion of the lesion. Note mitotic activity.

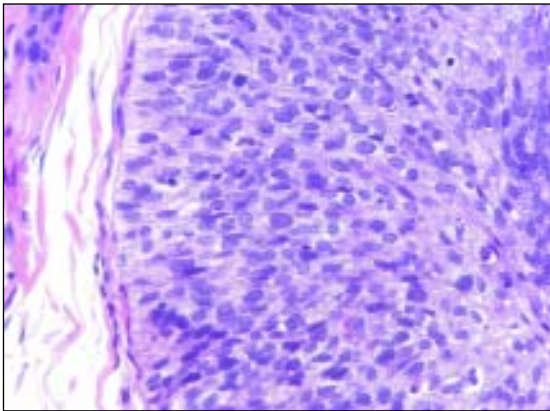


Figure 23

**Figure 23:** Tricholemmal carcinoma: periphery of the tumor showing outer root sheath differentiation with prominent basement membrane, peripheral palisading, clear cells, prominent intercellular bridges. Note moderate heterochromasia and pleomorphism of the nuclei, and apoptotic bodies.

## Acknowledgements

We are grateful to Dr. Lisa Lerner (Newton, MA) for providing the discussed case.

## References

1. Ackerman AB, Wade TR. Tricholemmoma. *Am J Dermatopathol* 2:207-24, 1980.
2. Brenn T, McKee PH. Tumors of the hair follicle. Chapter 17 In: McKee PH, Calonji E, Granter SR (eds). *Pathology of the Skin and Clinical Correlations*, 3<sup>rd</sup> ed. Philadelphia: Elsevier Mosby, pp 1537-1530.
3. Goldman L, Richfield DF. Tricholemmoma clinical lesions. *Arch Dermatol* 113:107-8, 1977.
4. Hanau D, Grosshans E. Tricholemmal tumor undergoing specific keratinization: "keratinizing trichilemmoma". *J Cut Pathol* 6:463-75, 1979.
5. Headington JT. Tricholemmoma. To be or not to be? *Am J Dermatopathol* 2:225-6, 1980.
6. Klein W, Chan E, Seukora JT. Tumors of the epidermal appendages. Chapter 30 In: Elder DE (ed). *Lever's Histopathology of the skin*, 9<sup>th</sup> ed. Philadelphia: Lippincott Williams & Wilkins, pp 883-886.
7. Reed RJ. Tricholemmoma. A cutaneous hamartoma. *Am J Dermatopathol* 2:227-8, 1980.
8. Richfield DF. Tricholemmoma. True and false types. *Am J Dermatopathol* 2:233-4, 1980.
9. Rollins TC. Tricholemmoma. *Am J Dermatopathol* 3:417, 1981.

Adriano Piris, Artur Zembowicz, Martin C. Mihm